Sagittal Plane Normalization for Patients with Idiopathic Scoliosis Using CAD/CAM

Introduction

The sagittal plane remains one of the most frequently overlooked planes when treating scoliosis. Although there is an understandable focus on the coronal plane Cobb angle correction, understanding sagittal plane normalization is also critically important. An exclusive focus on aggressive Cobb angle correction from scoliosis bracing and other scoliosis treatments can, in some cases, cause negative compensations of the spine and body. These can include migration of the main thoracic curve to a proximal thoracic curve and/or disharmonic or poor sagittal profiles. This is especially true when the scoliosis presents with severe structural changes of the spine and pelvis. Furthermore, the wide range of normal thoracic kyphosis and lumbar lordosis angles in the sagittal plane may contribute to misunderstandings of what optimal sagittal alignment should be.

The goals of scoliosis brace treatment should be to achieve three-dimensional correction and/or prevention of scoliosis progression, as verified radiologically, and to improve the clinical presentation (morphology) of the patient in and out of the brace during and at the end of growth.

Terms

Regions and sub-regions

Measurements of the regions and sub-regions of the sagittal plane, (see figure 1), were taken in the latero-lateral projection x-ray. The regional angles according to the Barcelona Scoliosis Physical Therapy School (BSPTS) are as the following:

Cervical: C1-C7

Cervico-thoracic: C7-T1

Proximal thoracic (or upper thoracic): T1-T5

Main thoracic: T5-T10

Thoracolumbar: T10-L2 (High TL T10-T12; Low TL T12-L2)

Lumbar: L1-L5 (or S1 according to SRS adult classification)

Lumbo-sacral: L5-S1

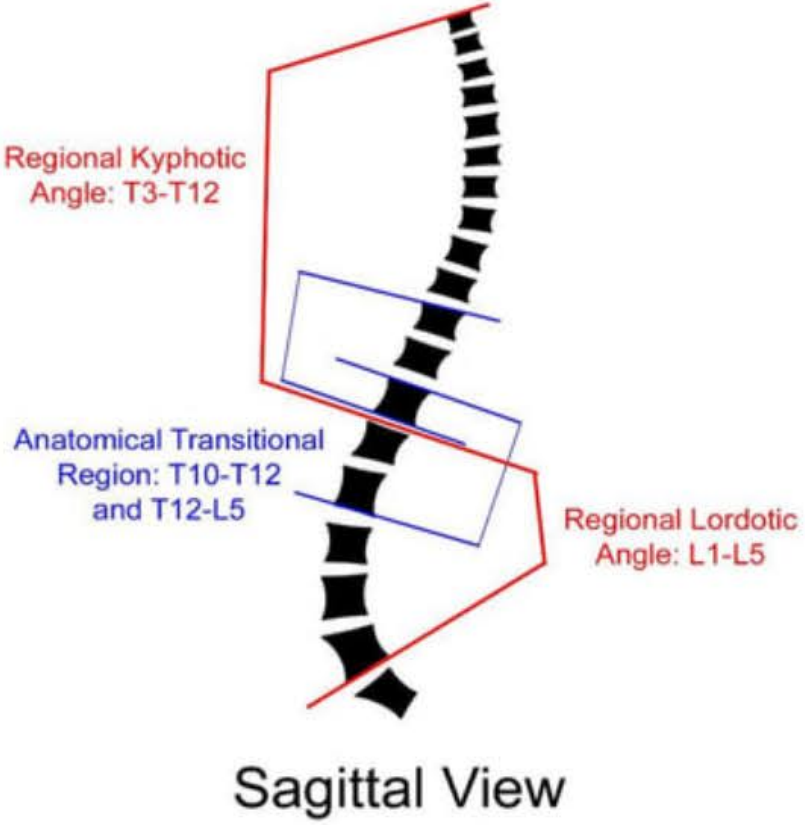
Regional Kyphotic Angle: T3-T12
Anatomical Transitional Region: T10-T12 and T12-L5
Regional Lordotic Angle: L1-L5
Sagittal View

Figure 1. Bernhard and Bridwell (1989) found the regional thoracic kyphotic Cobb angles were measured from T3-T12 and the regional lumbar lordotic Cobb angles were measured from L1-L5. The anatomical transitional regions were measured from T10-T12 (top) and T12-L2 (bottom).

Bernhard and Bridwell in 1987 also found the mean thoracic kyphosis was 36 degrees (standard deviation [SD], ± 10 degrees), ranging from the minimum value of 9 degrees to a maximum of 53 degrees. The mean upper thoracolumbar junction (T10-T12) Cobb measurement was 5.5 degrees of kyphosis (SD, ± 4 degrees), ranging from 3 degrees of lordosis to 20 degrees of kyphosis. The mean lower thoracolumbar junction (T12-L2) measurement was a negative 3 degrees of lordosis (SD of ±7 degrees) with a range from a negative 23 degrees of lordosis to 13 degrees of kyphosis. The lumbar lordosis averaged a negative 44 degrees (SD± 12 degrees), ranging from a negative 14 degrees to a negative 69 degrees, see figures 2 and 3. The means for the sagittal plane alignment did not significantly differ when adjusted for age and gender. (2)

Bradford, of Moe's textbook, found the range of thoracic kyphosis to be 20 to 45 degrees in a growing child and deemed that one greater than 45 to 50 degrees was excessive. (3)

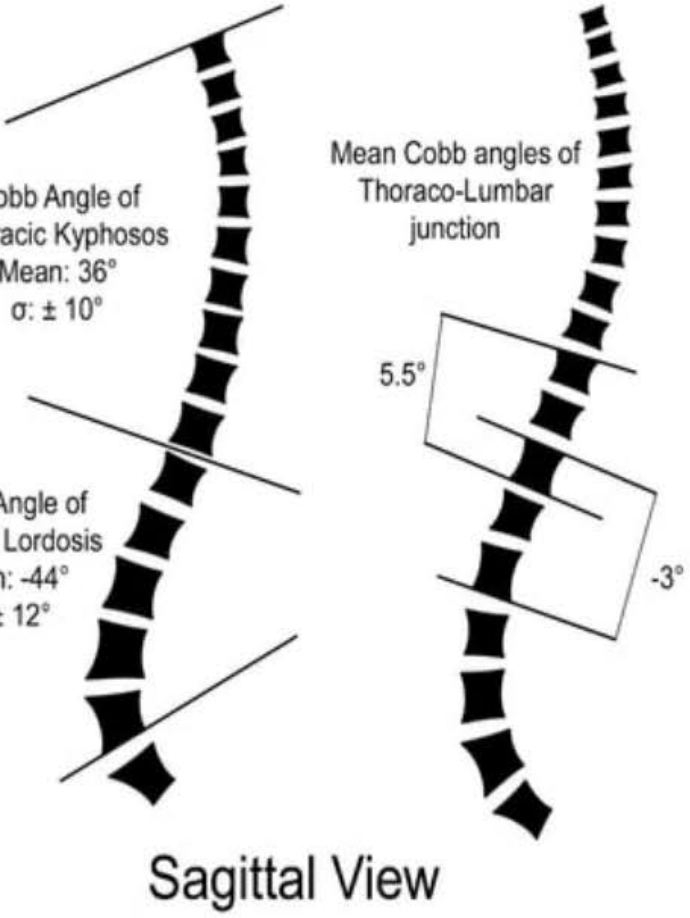

Figure 2. The mean thoracic kyphosis and mean lumbar lordosis angles were found in patients with sagittal curvatures (mean age 12.8 years old) of the spine as follows: The mean regional thoracic kyphotic Cobb angle was 36° ± 10°.The mean regional lumbar lordotic angle was -44° ± 12°. The anatomical transitional Regions were (top) T10-T12 5.5° SD, ± 4 degrees), and (bottom) T12-L2 -3°SD, ± 7 degrees).

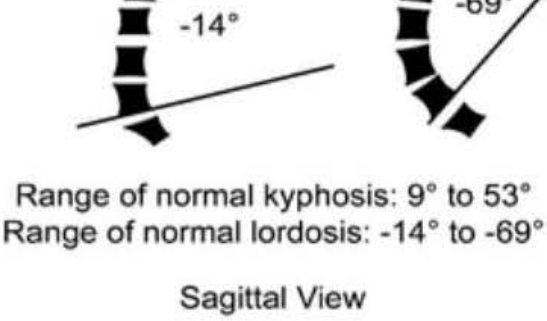
9°
53°
-14°
-69°
Range of normal kyphosis: 9° to 53°
Range of normal lordosis: -14° to -69°
Sagittal View

Figure 3. The minimum and maximum ranges of normal regional thoracic kyphosis (9 degrees to 53 degrees) and the ranges of normal regional lumbar lordosis (-14 degrees to -69 degrees).

The thoracic region is normally kyphotic and the lumbar region lordotic, with a smooth transition–from the slightly kyphotic sub-region T10 to T12 to the slightly lordotic sub-region T12 to L2. Stokes reported at the SRS work group in 1994 that the restricted sagittal Cobb angle was more accurate than the regional angle in order to define thoracic kyphosis and flat back (see figures 4 and 5c). (4, 5)

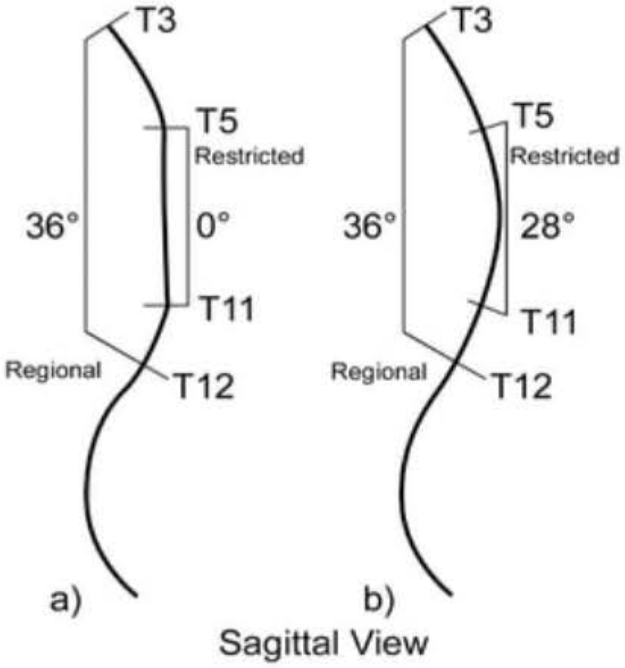

Figure 4, a and b. Both examples above measured 45 degrees Cobb angle in the coronal plane and both of the regional angles were 36 degrees. However, restricted thoracic kyphosis angles were different (a). The regional thoracic kyphosis angle measured from T3to T12 was 36 degrees and the restricted thoracic kyphosis angle measured from T5 to T11 (the end vertebrae of the coronal plane scoliotic curve) measured 0 degrees. (b): The regional thoracic kyphosis angle measured from T3to T12 was 36 degrees and the restricted thoracic kyphosis angle measured from T5 to T11 (the end vertebrae of the coronal plane scoliotic curve) measured 28 degrees.

Topographic Measurements

Guy Mellin in 1986 found means of topographic measurements (postural lordosis and kyphosis) in the sagittal plane, using a Myrin inclinometer, to be 31 degrees kyphosis and 23 degrees lordosis. (6) These baseline measurements are important to consider when designing the scoliosis brace. It is not the objective of the brace design to put every patient's back shape topographically at 31 degrees kyphosis and 23 degrees lordosis or the spine radiologically at 36 degrees kyphosis and -44 lordosis. Rather, it is to align it to an angle that is perhaps towards these numbers and sagittal plane normalization , while keeping the transition point from lordosis to kyphosis at the correct levels. Moreover, the sagittal plane alignment should be well accepted by each patient once in the brace.

Scheuermann Disease and Flatback

Scheuermann in 1920 first outlines the radiographic manifestation of this deformity, and noted that it was caused by wedging of the vertebral bodies. However, the cause of Scheuermann's disease remains unknown (figure 5b).

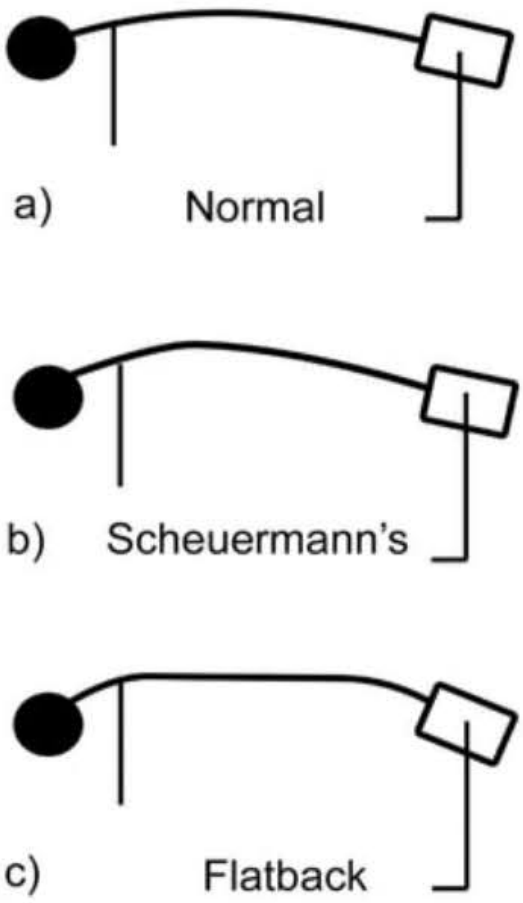

Figure 5. Morphological profile of the trunk in the sagittal view during forward bending: (a) normal shape, smooth and gradual segmental arch-shape, (b) Scheuermann's disease: a sharp drop off in the thoracic region, similar to a rampant round arch. (c) Thoracic flatback: a flat appearance from the lumbar to thoracic region.

Many factors are considered when determining the optimal sagittal plane alignment of the CAD model (as well as a positive mold from a cast). These include analysis of the radiographic structural alterations of the vertebral column, as well as the clinical presentation, including physical evaluation of the patient. The X-ray may present with structural changes of the vertebral column, which may significantly determine how much the sagittal plane will improve, independently of the patient's flexibility. (7 ,8)

The goal is to incorporate individualized sagittal plane normalization of the patient. In many cases it would be unrealistic to expect a patient with sagittal plane lumbar Cobb angle of -69 degrees, with significant structural changes, to achieve in-brace correction to -44 degrees, without risking negative compensations. Thus, the orthotist's evaluation of a patient should culminate in a more realistic amount of Cobb angle correction, consistent with sagittal plane normalization. These considerations likewise apply to thoracic kyphosis, insofar as it would be unrealistic to expect a patient with sagittal plane thoracic Cobb angle of 9 degrees, with significant structural changes, to achieve in-brace correction of the Cobb angle to 36 degrees, without possible negative compensations.

CAD/CAM

The previously discussed information from this article has many clinical applications, and should serve to facilitate scoliosis decision-making and brace design when determining sagittal plane normalization for each patient. Application of these principles dictated shifting the lumbar section of the trunk 10 mm posteriorly and bending the model above the waist 3 degrees ventrally (see figure 6).



Figure 6. Correction of the sagittal plane of a patient with AIS using Rodin 4D CAD software. The lumbar lordosis in this case is reduced from 40 degrees to 31 degrees and the thoracic kyphosis was increased to provide sagittal plane normalization. The sagittal plane was further improved by hand-modifications, once the CAD shape was carved by the Rodin carver.

Previous failures in brace design and other treatments can make future brace treatment and PT (Schroth-based PT and BSPTS) more difficult. An imbalance in biomechanical forces from poor brace design could yield good correction of the Cobb angle in the X-ray, yet disastrous consequences in other planes (see figure

7a).

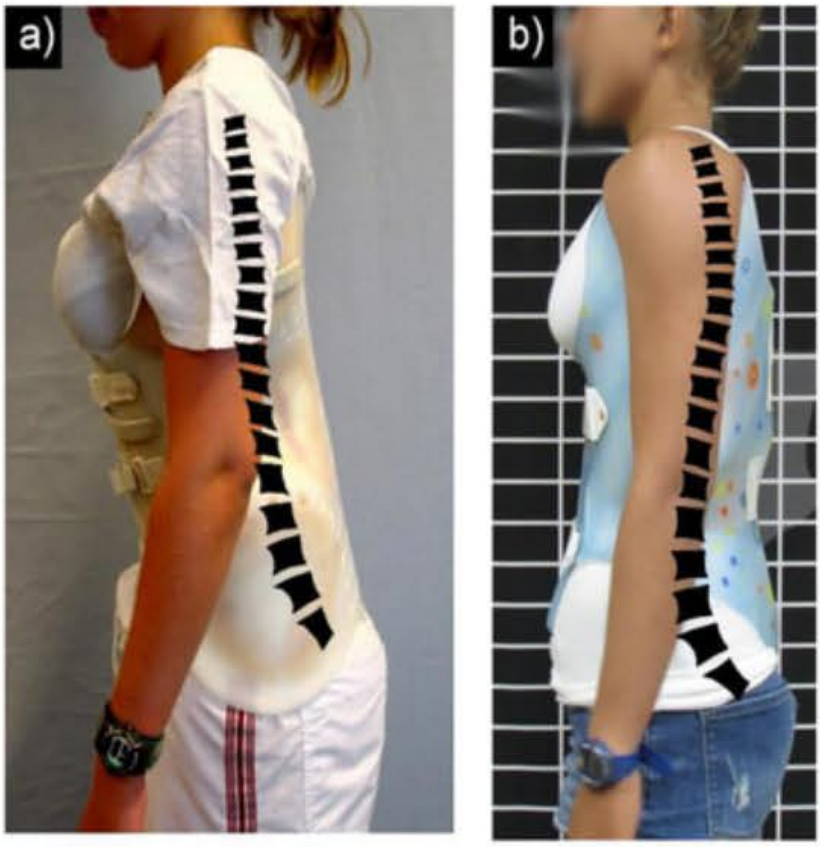

Disharmonic/Poor Sagittal Configuration

Harmonic/Sagittal Plane Normalization in a WCR Brace

Figure 7. a) Disharmonic sagittal configuration: a patient with AIS presents with a scoliosis brace that had good X-ray correction of the coronal plane thoracic and lumbar Cobb angles, at the cost of a poor sagittal curvature. b) Harmonic sagittal configuration: a patient with AIS presents with a Wood Cheneau Rigo (WCR) brace with good 3D correction, including sagittal plane normalization.

Conclusion

The focus of orthotic treatment of scoliosis has evolved from a nearly exclusive emphasis on correction of the obvious coronal plane deformity to an appreciation of scoliosis as a three-dimensional deformity, both radiographically and clinically.

Sagittal plane normalization and derotation of the transverse plane deformity are increasingly recognized as important scoliosis bracing goals. Normal alignment of the coronal and transverse planes is easily defined, but normal sagittal plane configuration has not yet been standardized. To a large extent, this is due to a significant range of normal values with respect to thoracic kyphosis and lumbar lordosis in the sagittal alignment of the spine.

Arbitrary benchmarks based on normal population values for thoracic kyphosis and lumbar lordosis should not be used in determining the extent of deviation. Information from this article has many clinical applications, and should help to facilitate individualized decision-making and brace design, incorporating basic principles of sagittal plane normalization into a comprehensive approach to the specific needs of each patient.

References

1. Wood G. Reversing Scoliosis and Brace Treatment of a Proximal Structural Curve. The O&P EDGE. 2014;13(3):58-64.

2. Bernhardt M, Bridwell KH. Segmental analysis of the sagittal plane alignment of the normal thoracic and lumbar spines and thoracolumbar junction. Spine. 1989;14(7):717-21.

3. Moe J, Lonstein J. Moe's Textbook Of Scoliosis And Other Spinal Deformities. Philadelphia: W.B. Saunders; 1995.

4. Stokes IA 1994 Three-dimensional terminology of spinal deformity. A report presented to the Scoliosis Research Society by the Scoliosis Research Society Working Group on 3-D terminology of the spinal deformity. Spine 19: 236-248.

5. Rigo M. Patient evaluation in idiopathic scoliosis: Radiographic assessment, trunk deformity and back asymmetry. Physiotherapy Theory Pract. 2011;27(1):7-25.

6. Mellin G. Measurement of thoracolumbar posture and mobility with a Myrin inclinometer. Spine. 1986;11(7):759-62.

7. Wood G. Brace modifications that can result in improved curve correction in idiopathic scoliosis. Scoliosis. 2014;9(1):2. doi:10.1186/1748-7161-9-2.

8. Wood G. Comparison of Surface Topography and X-ray Values During Idiopathic Scoliosis Treatment Using the Chêneau Brace (the Chêneau Brace System). 2003.